



Intestinal Obstruction in Dromedary Camels: Clinical and Ultrasonographic Findings as Well as Variations in Acid-base Balance, Blood Gases and Hematobiochemical Profiles

Mohamed Tharwat ^{1,2*}, Saleh Alkhedhairi³ and Mohamed Marzok ^{4,5}

¹Department of Clinical Sciences, College of Veterinary Medicine, Qassim University, P.O. Box 6622, Buraidah, 51452, Saudi Arabia

²Department of Animal Medicine, Faculty of Veterinary Medicine, Zagazig University, 44519, Zagazig, Egypt

³Department of Medical Biosciences, College of Veterinary Medicine, Qassim University, P.O. Box 6622, Buraidah, 51452, Saudi Arabia

⁴Department of Clinical Sciences, College of Veterinary Medicine, King Faisal University, Al-Ahsa, Saudi Arabia

⁵Department of Surgery, Faculty of Veterinary Medicine, Kafr El Sheikh University, Kafr El Sheikh, Egypt

*Corresponding author: atieh@qu.edu.sa

ABSTRACT

This study was performed to investigate the variations of acid-base balance, blood gases and hematobiochemical panels in camels with intestinal obstruction. Thirteen dromedary camels with obstructions of the intestines were used, with 15 healthy controls. Bilateral enlargement of the abdomen was the most common sign in the diseased camels. Abdominal sonography revealed intestinal enlargement, and 4 of the diseased camels had peritoneal effusions. The pH value was lower, while the concentration of PCO₂ was significantly higher than healthy group. The concentrations of HCO₃ and TCO₂ were also significantly higher versus healthy camels. However, the concentration of lactic acid was significantly lower than healthy camels. Leukocytosis, neutrophilia and lymphopenia were the only noticeable hematological changes in diseased camels. The concentrations of the total proteins increased above the levels in healthy camels. In contrast, the serum concentration of albumin was significantly low in diseased. Significant hyperglycemia was evident compared to controls. The serum activities of the enzymes alkaline phosphatase (ALP), aspartate aminotransferase (AST) and creatine kinase (CK) were significantly higher in diseased versus healthy group; however, the serum activity of the enzyme γ -glutamyl transferase (GGT) was significantly lower. In conclusion, when compared to the picture of healthy camels, a moderate metabolic acidosis, was found in camels with intestinal obstruction. Opposite, lactate levels were significantly elevated in diseased camels. Neutrophilic leukocytosis with lymphopenia was the only noticeable hematological change. However, several blood metabolites differed including hypoalbuminemia, hyperglycemia, decreased serum activity of GGT and increased serum activities of ALP, AST and CK.

Keywords: Camel, Acid-base balance, Blood gases, Biomarkers, Intestinal obstruction.

Article History

Article # 24-680

Received: 23-Jun-24

Revised: 18-Jul-24

Accepted: 30-Jul-24

Online First: 31-Jul-24

INTRODUCTION

Disorders of the gastrointestinal tract are more frequent in the dromedaries than those affecting the renal, hepatic, respiratory, cardiovascular, nervous and musculoskeletal systems (Tharwat, 2024). Affections of the small and large intestines principally obstructions, volvulus, strangulation and intussusceptions are more common in camels with pica or depraved appetite (Ramadan et al.,

2008). The length of the small and large intestines that average 40 and 19.5m, respectively is a predisposing factor for these affections. Obstruction of the intestines is mostly observed in farm animals suffering from nutritional deficiencies (Braun et al., 2023a,b; Mair and Sherlock, 2023). The procedure results in most cases in huge economic losses consisting of deaths of the affected animals. Abdominal disorders are recently discovered in camels using abdominal ultrasound (Tharwat, 2024).

Cite this Article as: Tharwat M, Alkhedhairi S and Marzok M, 2024. Intestinal obstruction in dromedary camels: clinical and ultrasonographic findings as well as variations in acid-base balance, blood gases and hematobiochemical profiles. International Journal of Agriculture and Biosciences xx(x): xx-xx. <https://doi.org/10.47278/journal.ijab/2024.131>



A Publication of Unique Scientific Publishers

A constant acid-base balance and blood gases are required in human beings as well as in animals (Quade et al. 2021). Any change in the equilibrium of the acid-base status and also in blood gases will subsequently influence the survival of the diseased animal (Tharwat et al., 2024). In the dromedaries, the influence of training and fluid loss on the status of acid base differences and blood gases has been reported (Abdoun et al., 2012; Okab et al., 2012). In young dromedaries, the effect of acid-load with NH₄Cl on the acid base variations and gases of blood has been also published (Elkhair and Hartmann, 2010). In camels, reports on the effect of infestation with ticks, electroejaculation and trypanosomiasis on the acid base and blood gases have also been found in published literature. More recently, the influence of difficult parturition in dromedaries on the acid base status and blood gases has also been investigated. Similarly, the status of acid base and gases of blood in camel calves with tick infestation has also been reported more recently (Tharwat et al., 2024).

Current investigation was performed to shed light on the variations of the acid-base balance, blood gases and hematobiochemical panels in camels with obstructions of the small and large intestines and compare it with values in healthy camels.

MATERIALS & METHODS

Camels, Past History and Clinical Examination

Experimental design has been reported recently (Almundarij and Tharwat, 2023). In brief, 13 dromedary camels (ten females and three males) with obstructions of the intestines were admitted to our clinic for investigation because of loss of defecation, enlargement of the abdominal circumference from both sides, chronic and/or recurrent tympany and complete loss of appetite for periods range from three days till nine days. Upon entrance, clinical examination of the diseased camels has been performed consisting of physical examination and inspection of the camels' behavior. Measurements of respiratory and pulse rates and rectal temperature were then carried out. Additionally, auscultation of the thoracic and abdominal organs was performed and principally, palpation, percussion and swinging of the abdomen was done transcutaneously and transrectally. Fifteen clinically healthy camels were used as a control group.

Blood Sampling, Diagnosis and Animal Ethics

The jugular vein was punctured in diseased camels to get 10mL of blood. Two milliliters were collected in tubes with the EDTA anticoagulant, other 2 milliliters were collected in tubes with heparin and the last 6 milliliters were evacuated in anticoagulant-free tubes for serum separation. Final diagnosis of obstruction of the intestines in the diseased camels was established dependent on past history, physical and laboratory examinations and thoracic and abdominal ultrasonography. The Ethical Committee of Laboratory Animals in the University of Qassim, Buraydah approved the experimental design of this study (SR-D-010-078).

Measurement of Acid-base Balance, Blood Gases, Lactic Acid and Hematobiochemical Levels

Heparin blood samples were tested immediately for estimating the variables of acid-base and gas levels using an animal-side commercial analyzer (I-STAT[®], Abaxis, California, USA). In this method, blood pH, partial pressure of carbon dioxide (PCO₂), bicarbonate (HCO₃), total carbon dioxide (TCO₂), and lactic acid were evaluated immediately (Tharwat et al., 2024). Differentials alongside the total leukocytic count, erythrocyte count, and percent of hematocrit, concentration of hemoglobin and indices of erythrocytes were carried out in blood samples collected in EDTA anticoagulant (VetScan HM5, Abaxis, California, USA). The level of blood parameters including total protein, albumin, alkaline phosphatase (ALP), aspartate aminotransferase (AST), γ -glutamyl transferase (GGT), creatine kinase (CK) and glucose were tested in sera samples (VetScan VS2 analyzer, Abaxis, California, USA).

Statistics

The results of camels with obstruction of the intestines and that of the healthy camels are expressed as mean \pm SD and were analyzed using the SPSS statistical program, version 18, 2009. The student's *t* test was performed for comparisons at a significant level of $P \leq 0.05$.

RESULTS

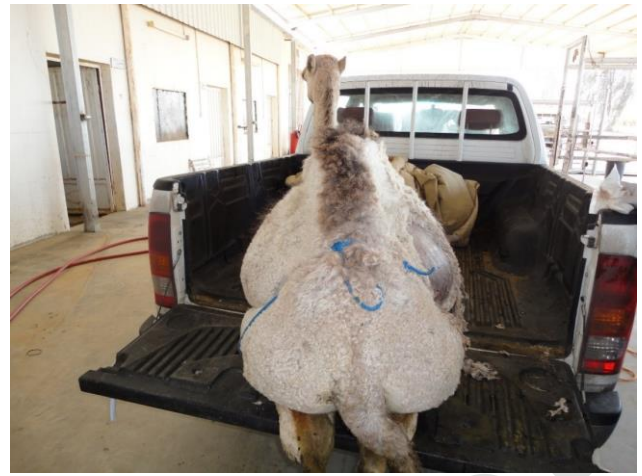Enlargement of the abdomen from both sides was the most common complaint in the presenting camels with obstruction of the intestines (Fig. 1). In five of the diseased animals (38.5%), passage of thick mucus was the most noticeable sign (Fig. 2). When ultrasonography was performed to the abdomen, intestinal enlargement was a common finding in all diseased camels. Four of the diseased camels (30.8%), had peritoneal effusions of hypoechoic fluid (Fig. 3).

The pH, blood gas parameters and concentration of lactic acid together with the 25, 50, 75, 95 and 99% percentiles versus healthy controls are listed in Table 1. In comparison to a pH value of 7.54 ± 0.16 in healthy animals, the pH value in diseased group measured 7.44 ± 0.08 with no significant difference between both groups ($P=0.12$). Contrast, the concentration of PCO₂ in diseased camels was significantly higher than that in controls (47.0 ± 5.3 versus 30.0 ± 8.1 mmHg; $P=0.01$). Similarly, the concentration of HCO₃ was significantly higher in diseased than in healthy camels (32.2 ± 7.9 versus 24.9 ± 2.9 mmHg; $P=0.03$). In a parallel way, the concentration of TCO₂ was significantly higher in diseased than in sound camels (33.5 ± 7.9 versus 25.7 ± 2.9 mmHg; $P=0.04$). On the other hand, the concentration of lactic acid in diseased camels was significantly lower than that in the healthy camels (2.6 ± 1.4 versus 4.3 ± 3.3 mmol/L; $P=0.001$).

Table 2 shows the hematological parameters in camels with obstruction of the intestines together with their percentiles of 25th, 50th, 75th, 95th and 99th compared to the healthy camels. Leukocytosis, neutrophilia and lymphopenia were the only noticeable hematological changes in diseased camels when in comparison to



A

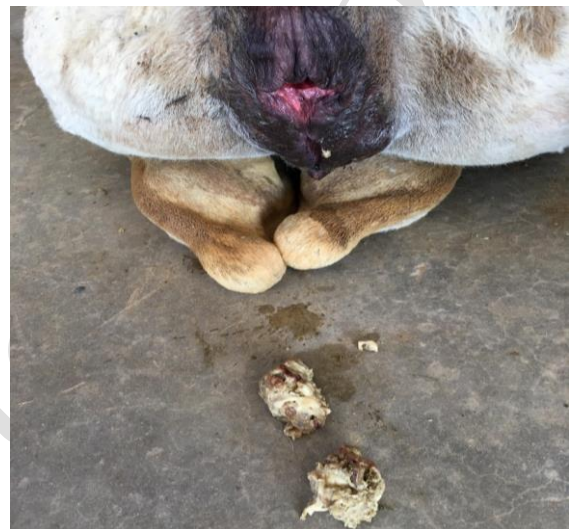


B

Fig. 1: Enlargement of the abdominal circumference in two female camels with intestinal obstruction.

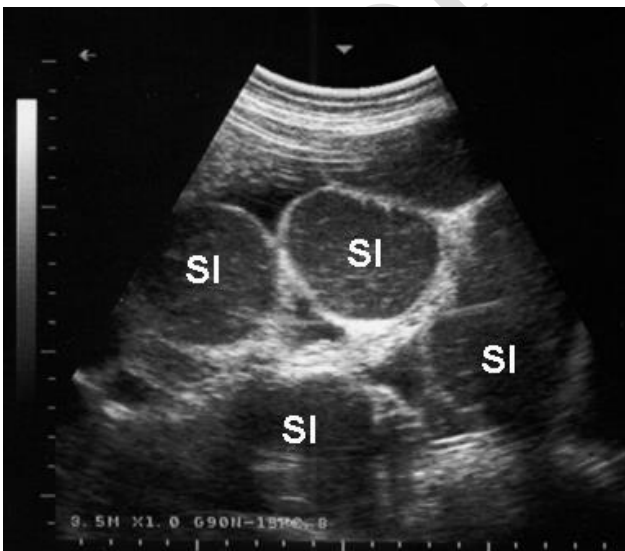

A

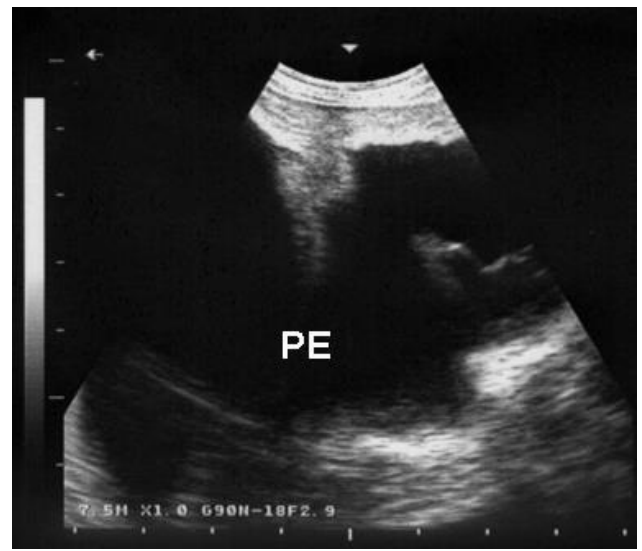


B

Fig. 2: Clinical presentation of a male (A) and female (B) with intestinal obstruction. The main owner complaints consisted of anorexia, abdominal distension and only mucus was passed from the rectum.



A



B

Fig. 3: Ultrasonographic findings in two female camels with intestinal obstruction. Both animals were presented with complete absence of feces, total loss of appetite and bilateral abdominal enlargement. Image A shows distension of the small intestinal (SI) loops while image B shows peritoneal effusions (PE).

Table 1: Acid-base balance, blood gases and lactic acid concentration in camels with obstruction of the intestines compared to healthy controls

Parameters	Units	Camels with intestinal obstruction (n=13)					Control camels (n=15)					P value		
		Mean±SD	Percentiles				Mean±SD	Percentiles						
			25%	50%	75%	95%		99%	25%	50%	75%		95%	99%
pH		7.44±0.08	7.38	7.41	7.50	7.52	7.54	7.54±0.16	7.44	7.54	7.70	7.77	7.79	0.12
PCO ₂	mmHg	47.0±5.3	44.55	48.1	50.75	52.28	52.54	30.0±8.1	22.6	31.6	36.7	40.9	40.9	0.01
HCO ₃	mmol/L	32.2±7.9	26.5	32.8	38.1	41.2	41.5	24.9±2.9	23.7	25.1	27.0	28.3	28.9	0.03
TCO ₂	mmol/L	33.5±7.9	28.0	34.0	39.3	42.5	42.9	25.7±2.9	24.8	26.0	27.3	29.1	29.8	0.04
LA	mmol/L	2.6±1.4	1.8	2.4	3.3	3.9	4.1	4.3±3.3	2.3	3.0	5.4	11.7	11.7	0.001

PCO₂, partial pressure of carbon dioxide; HCO₃, bicarbonate; TCO₂, total carbon dioxide; LA, lactic acid.

Table 2: Hematological variables in camels with obstruction of the intestines compared to healthy controls

Parameters	Camels with intestinal obstruction (n=13)					Healthy camels (n=15)					P value		
	Mean ± SD	Percentiles				Mean ± SD	Percentiles						
		25%	50%	75%	95%		99%	25%	50%	75%		95%	99%
WBCs (×10 ⁹ /L)	20.9±4.5	12.36	13.8	30.1	39.4	44.3	16.8±3.9	15.7	17.9	18.6	21.3	22.3	0.04
LYM (×10 ⁹ /L)	1.5±0.7	1.2	1.3	2.1	2.5	2.6	6.2±2.9	4.4	5.9	6.6	11.1	12.9	0.001
NEU (×10 ⁹ /L)	18.9±12.1	10.1	12.3	26.7	37.2	41.9	9.7±3.0	7.6	9.8	12.0	13.8	14.3	0.001
RBCs (×10 ¹² /L)	10.6±1.9	9.6	10.5	11.3	13.2	13.8	11.3±1.4	10.4	11.5	12.0	13.5	13.6	0.5
HB (g/dL)	15.0±3.4	13.6	15.0	15.5	20.2	21.6	16.4±2.8	14.6	16.0	18.0	21.0	23.0	0.7
PCV (%)	28.4±8.2	24.0	28.1	29.9	43.5	44.7	28.9±2.7	27.4	29.0	30.5	33.0	33.2	0.8
MCV (fl)	24.8±3.8	23.0	26.0	27.0	28.8	29.8	25.5±1.5	24.0	26.0	26.0	27.1	27.8	0.2
MCH (pg)	14.2±1.5	13.0	13.7	15.4	16.3	16.6	14.7±2.4	12.7	13.9	16.7	18.7	19.7	0.8
MCHC (g/dL)	57.8±6.3	52.1	59.8	61.6	65.7	67.9	57.6±9.0	50.6	53.7	64.3	74.3	74.9	0.9

WBCs, white blood cells; LYM, lymphocytes; MON, monocytes; NEU, neutrophils; RBCs, red blood cells; HB, hemoglobin; PCV, packed cell volume; MCV, Mean corpuscular volume; MCH, Mean corpuscular hemoglobin; MCHC, Mean corpuscular hemoglobin concentration

Table 3: Biochemical parameters in camels with obstruction of the intestines compared to healthy controls

Parameters	Camels with intestinal obstruction (n=13)					Healthy camels (n=15)					P value		
	Mean ± SD	Percentiles				Mean ± SD	Percentiles						
		25%	50%	75%	95%		99%	25%	50%	75%		95%	99%
TP (G/L)	73.4±12.6	67.5	75.0	81.0	88.2	89.6	67.3±4.3	63.0	67.5	68.8	74.0	76.4	0.09
ALB (G/L)	26.2±28.2	44.5	50.0	55.5	60.9	62.6	60.39±3.0	60.8	61.5	62.0	64.3	64.9	0.001
ALP (U/L)	93±64	53	57	110	190	217.16	6.6±2.8	5.8	6.5	8.0	10.8	12.6	0.0001
AST (U/L)	302±334	110	110	399	630	676.44	79.5±16.5	69.5	80.5	85.0	104.8	118.6	0.0001
GGT (U/L)	8.3±4.2	6	7	10	12	12.88	12.2±5.3	8.8	12.5	13.0	19.8	26.4	0.005
CK (U/L)	262±88	230	262	293	318	323	139.0±21.6	127.0	136.0	148.8	171.8	178.4	0.0001
GLU (MG/DL)	197±58.5	146	203	230	272.3	286.46	103±11	96	101	110	115	119	0.001

TP, total protein; ALB, albumin; ALP, alkaline phosphatase; AST, aspartate aminotransferase; CA, calcium; GGT, γ-glutamyl transferase; CK, creatine kinase; MG, magnesium; GLU, glucose.

healthy animals (P=0.04, 0.001 and 0.001, respectively). Other parameters including erythrocytes count, percent of hematocrit, concentration of hemoglobin and indexes of erythrocytes including mean corpuscular volume, mean corpuscular hemoglobin and mean corpuscular hemoglobin concentration did not show any significant alterations (P>0.05).

The biochemical variables in diseased versus healthy camels alongside the 25, 50, 75, 95 and 99percentiles are summarized in Table 3. In diseased animals, the concentrations of the total proteins exceeded the levels in healthy camels; however, did not reach a significant level (P=0.09). In contrast, the serum concentration of albumin was significantly low in diseased compared to healthy group (P=0.001). Hyperglycemia was very evident in camels with intestinal obstructions compared to controls (P=0.001). The serum activities of the enzymes ALP, AST and CK were significantly higher in diseased versus healthy group (P=0.0001). However, the serum activity of the enzyme GGT was significantly lower in the diseased than healthy camels (P=0.005).

DISCUSSION

Abdominal distension is a common presentation for camels suffering from intestinal obstruction (Köhler-Rollefson et al., 2001; Fowler, 2010). The majority of dromedary camels presented to veterinary clinics are often

due to gastrointestinal problems. In current investigation, camels were referred to our hospital because of complete loss of appetite, passes of no feces with clean rectum, remarkable bilateral distension of the abdomen and chronic and/or recurrent tympany. Inspection on the initial view of the camels was shocking as the abdomen resembled a huge pear weighing of approximate 500kg in some cases. Over thirty-eight of the resented cases passed very thick mucus from the rectum. In over thirty of the camels and because of the severe distension of the intestines, effusion of anechoic peritoneal fluids was easily visualized. To our best information, the present report is the principal which emphasizes the picture of the balance of the acid base and blood gases in conjunction with hematological and biochemical panels.

Final diagnosis depended collectively on the history of the case, clinical examination and laboratory and ultrasonographic findings. By the later technique, we could determine the actual obstruction site in most cases, estimate the degree of intestinal distension, image the peritoneal effusions if present and visualize the hypomotility of the intestines or the complete disappearance of intestinal motility as reported. As published by our groups, it was clarified that routine scanning of abdominal organs in diseased camels by ultrasound has led to verification and prognosis of animals suffering in most cases from unhelpful case history, non-specific clinical manifestations and even the laboratory

results were unremarkable (Tharwat, 2024). Sonography has also been reported as an ancillary methodology for the detection of common etiologies of abdominal distension in cattle and equines (Braun et al., 1995; Braun, 2005; Taylor et al., 2010).

The kidney regulates acid base balance through the process of reabsorption of excreted HCO_3^- and, formation of HCO_3^- through production of ammonia, and by secretion of acid into the urine (Chen et al. 2019). In the camels with obstruction of the intestines in present report, a moderately acid pH was detected in diseased camels. Similar findings were found in camels with renal dysfunction in camels (Tharwat, 2023). This may be justified by the elevated TCO_2 concentrations in sick animals. However, the concentration of HCO_3^- in diseased camels was relatively lower than that in controls; a result may be explained on the complete absence of feces. Interestingly, lactate concentration in the sick camels were significantly higher than those in sound camels. Later finding may be due to general weakness and long-term recumbency of the camels with intestinal obstruction as lactic acid is considered a waste of exercise and also produced from various body systems (Tharwat et al., 2024)

Coming to the hematological data, neutrophilic leukocytosis parallel to lymphopenia were the most outstanding differences. This may refer to secondary or even primary bacterial infection. The observed condition of neutrophilic leukocytosis has also been reported in dromedary camels with intestinal obstruction (Tharwat, 2024). Contrary to hematological findings, several blood metabolites differed significantly when matched with values in healthy group. A non-significant elevation of total serum proteins was found in diseased versus healthy camels. However, increased blood glucose level and increased serum activities of ALP, AST and CK were detected. On the opposite side, albumin concentration and the serum activity of GGT decreased in a significant manner with obstruction of the intestines compared to healthy ones.

In conclusion, when compared to the picture of acid base levels and blood gases in healthy camels, a moderate metabolic acidosis, based on the increases in TCO_3 , was found in camels with intestinal obstruction. However, the bicarbonate concentration was decreased in camels with intestinal obstruction in comparison to controls. On the contrary, lactate levels were significantly elevated in diseased versus healthy camels. Neutrophilic leukocytosis with lymphopenia was the only noticeable hematological differences. However, several blood metabolites differed including hypoalbuminemia, hyperglycemia, decreased serum activity of GGT and increased serum activities of ALP, AST and CK.

Author Contributions

MT: conceived, designed the experiments and carried out the practical work. SA: carried out the laboratory work. MT: wrote the manuscript draft, prepared the figures and tables. MM has revised the manuscript draft.

All authors re-read, revised and approved the manuscript.

Conflict of Interest Statement

The authors declare that there is no conflict of interest.

REFERENCES

- Abdoun, K.A., Samara, E.M., Okab, A.B., and Al-Haidary, A.A. (2012). State of acid-base balance in dehydrated camels (*Camelus dromedarius*). *Asian Journal of Animal and Veterinary Advances*, 7(5): 420-426. <https://doi.org/10.3923/ajava.2012.420.426>
- Almundarij, T.I., and Tharwat, M. (2023). Impact of intestinal and urinary tracts obstruction on oxidative stress biomarkers in dromedary camels. *International Journal of Veterinary Science*, 12(3): 422-427. <https://doi.org/10.47278/journal.ijvs/2023.009>
- Braun, U., Gerspach, C., Loss, S., Hilbe, M., and Nuss, K. (2023a). Small intestinal strangulation in 60 cattle - clinical, laboratory and ultrasonographic findings, treatment and outcome. *BMC Veterinary Research*, 19(1), 233. <https://doi.org/10.1186/s12917-023-03797-9>
- Braun, U., Gerspach, C., Volz, C., Boesiger, M., Hilbe, M., and Nuss, K. (2023b). A retrospective review of small intestinal intussusception in 126 cattle in Switzerland. *Veterinary Record Open*, 10(1), e58. <https://doi.org/10.1002/vro2.58>
- Braun, U. (2005). Ultrasound as a decision-making tool in abdominal surgery in cows. *Veterinary Clinics of North America: Food Animal Practice*, 21(1), 33-53. <https://doi.org/10.1016/j.cvfa.2004.11.001>
- Braun, U., Marmier, O., and Pusterla, N. (1995). Ultrasonographic examination of the small intestine of cows with ileus of the duodenum, jejunum or ileum. *Veterinary Record*, 137(9), 209-215. <https://doi.org/10.1136/vr.137.9.209>
- Chen, W., Levy, D.S., and Abramowitz, M.K. (2019). Acid Base balance and progression of kidney disease. *Seminars in Nephrology*, 39(4), 406-417. <https://doi.org/10.1016/j.semnephrol.2019.04.009>
- Elkhair, N., and Hartmann, N. (2010). Studies on acid-base status (Stewart's model) of young camels (*Camelus dromedarius*) after acid-load with NH_4Cl . *Berliner und Münchener tierärztliche Wochenschrift*, 123(3-4), 153-159.
- Fowler, M.E. (2010). Parasites. In *Medicine and Surgery of Camelids*, third Edition. Blackwell Publishing, Iowa, pp., 231-269.
- Köhler-Rollefson, I., Mundy, P., and Mathias, E. (2001). Managing and treating camels. In *A Field Manual of Camel Diseases: Traditional and Modern Healthcare for the Dromedary*. ITDG Publishing, London, pp., 1-67.
- Mair, T., and Sherlock, C. (2023). Recurrent Colic: Diagnosis, Management, and Expectations. *Veterinary Clinics of North America: Equine Practice*, 39(2), 399-417. <https://doi.org/10.1016/j.cveq.2023.03.014>
- Okab, A.B., Abdoun, K.A., Samara, E.M., and Al-Haidary, A.A. (2012). Acid-Base Balance in Camels (*Camelus dromedarius*): Effects of Exercise and Dehydration. *The FASEB Journal Experimental Biology Meeting Abstracts*, First published: 01 April 2012 https://doi.org/10.1096/fasebj.26.1_supplement.lb739
- Quade, B.N., Parker, M.D., and Occhipinti, R. (2021). The therapeutic importance of acid-base balance. *Biochemical Pharmacology*, 183, 114278. <https://doi.org/10.1016/j.bcp.2020.114278>
- Ramadan, R.O., Abdin-Bey, M.R., and Mohamed, G.E. (2008). Intestinal obstruction in camels (*Camelus dromedaries*). *Journal of Camel Practice and Research*, 15(1), 71-75.
- SPSS. (2009). *Statistical Package for Social Sciences*, SPSS Inc., Chicago, IL, USA Copyright© for Windows, version 16.0.
- Taylor, F.G.R., Brazil, T.J., and Hillyer, M.H. (2010). Alimentary diseases. In *Diagnostic Techniques in Equine Medicine*. 2nd Ed, Saunders, pp: 28-72.
- Tharwat, M. (2023). Changes in acid-base balance, blood gases and hemato-biochemical parameters in Arabian camels with different urinary tract disorders. *International Journal of Veterinary Science*, 12, 724-729. <https://doi.org/10.47278/journal.ijvs/2023.026>
- Tharwat, M. (2024). Fundamentals of diagnostic ultrasound in dromedary camel medicine. *International Journal of Veterinary Science*, 13(1), 1-6. <https://doi.org/10.47278/journal.ijvs/2023.057>
- Tharwat, M., El-Ghareeb, W. R., and Alkheraif, A. A. (2024). Acute phase proteins, hemato-biochemical profiles, acid-base balance and blood gas alterations in camel calves infested with ticks. *International Journal of Veterinary Science*, In press. <https://doi.org/10.47278/journal.ijvs/2024.146>